

Review Article

External Skeletal Fixator to Stabilize the Orthopedic Conditions in Avian Species: A Systematic Review of Case Reports and Case Series

Hossein Taiyari and Jalila Abu*

Department of Veterinary Clinical Studies, Faculty of Veterinary Medicine, Universiti Putra Malaysia, 43400 UPM, Serdang, Selangor, Malaysia

ABSTRACT

Orthopedic conditions are among the most frequent avian emergency cases admitted to veterinary hospitals and clinics. An external skeletal fixator is commonly used as surgical treatment in avian orthopedics. This review aimed to systematically evaluate the use of external skeletal fixator (ESF) in published cases of avian orthopedics. Four electronic databases were searched to identify all relevant case reports and case series. Altogether, 24 primary reports met the inclusion criteria. Of those, 16 reports were case reports; and eight were case series. In total, 166 avian patients with different orthopedic conditions were undergone ESF stabilization techniques; and raptor species formed the majority of the patients. The characteristics of the fractured bone were the key factor in the suitability of different ESF techniques. In addition, other factors such as type, location, and severity of the orthopedic condition should be considered. ESF implants are promising techniques for treating avian orthopedic conditions, as the complications related to the fixators were few, and the percentage of successfully released raptors was high. Unfortunately, there are so many cases of avian orthopedics that were not published. Considering this caveat, it is not easy to draw a firm conclusion on this topic. However, this paper can serve as a guiding principle for clinicians.

Keywords: Avian orthopedics, external skeletal fixator, fracture, luxation, raptor species, systematic review

ARTICLE INFO

Article history:

Received: 23 October 2021

Accepted: 03 February 2022

Published: 20 April 2022

DOI: <https://doi.org/10.47836/pjst.30.3.04>

E-mail addresses:

hosseintaiyari@gmail.com (Hossein Taiyari)

jalila@upm.edu.my (Jalila Abu)

* Corresponding author

INTRODUCTION

Orthopedic disorders in avian patients are mainly inclusive of fractures and luxations. These conditions are of great importance in avian medicine practice, especially when it comes to the admissions of birds of prey to veterinary clinics and hospitals (Harcourt-

Brown, 2002; Buttle, 2004; Helmer & Redig, 2006). Raptors are sensitive to changes in their surroundings and are susceptible to trauma caused by crashing into cars or artificial obstacles (Fix & Barrows, 1990). A gunshot is also a common cause of fractures and can cause nerve damage through lead toxicity, which may worsen the prognosis of the injured birds (Bennett, 1994). The main goals in fracture management are stabilization and length maintenance after achieving fragments alignment (Ponder & Redig, 2016; Carrasco, 2019). Both internal and external skeletal fixator provides a substantial reduction in the movement of the injured site, which ultimately enhances the recovery of both fractures and luxations (Redig & Ponder 2016). Although most of the techniques and principles used in fracture management in birds are similar to mammals, anatomic and physiologic particularities lead to different preferences for surgical approaches between avian and non-avian species (Tully Jr., 2002; Carrasco, 2019). One of the main differences is the more favorable outcome of using an external skeletal fixator (ESF) in avian orthopedic cases (Carrasco, 2019). An external skeletal fixator (ESF) is commonly used in two-dimensional space where its holding pins pass through both cortices. If the pins extend to the other side and attach to the second external bar, it is called ESF type 2. Otherwise, it is called ESF type 1 (Carrasco, 2019). Recently, a novel multidimensional ESF technique, namely key ring or circular fixator, has been developed to stabilize the avian long bone fractures (Katogiritis et al., 2019). The combination of ESF with an intramedullary (IM) pin is called a tie-in fixator (TIF) which is considered one of the most rigid and commonly used stabilization techniques in the treatment of avian orthopedic conditions (Bueno et al., 2015; Van Wettere et al., 2009; Carrasco et al., 2017). In addition, ESF can be practical for applying for recent advances in the avian orthopedic field like bone grafts and bone matrix (Jones & Redig, 2001; Jalila et al., 2004).

This paper aims to summarize and critically evaluate the published studies that used ESF to stabilize and ultimately promote the recovery of avian orthopedic conditions.

MATERIALS AND METHODS

This systematic review followed the principles of both PRISMA (Preferred Reported Items for Systematic Review and Meta-Analyses) guideline and the Cochrane Handbook for Systematic Reviews of Interventions (Liberati et al., 2009; Moher et al., 2009).

Search Methods and Inclusion Criteria

Literature has been explored using the electronic search of the keywords in the following databases: Scopus, PubMed, Veterinary Information Network (VIN), and Google Scholar. In order to reduce the possibility of missing the relevant studies, a wider category of keywords was used. The details of the electronic search can be found in Appendices A and B.

The inclusion criteria of the primary studies were based on PICOS (Population, Intervention, Comparison, Outcomes, Study design).

All species of birds that participated in avian orthopedics case reports (CRs) or case series (CSs) were considered the study population.

The primary outcome was shown by describing the different ESF used to stabilize various avian orthopedic conditions. These include the percentage of each type of ESF used in different orthopedic conditions, the release percentage of raptors, and the mean time spent for each type of ESF to stabilize the fractures and luxations.

The secondary outcome was mainly related to the healing failures and consisted of complications of external fixation (major, minor, the effect of these complications on the fracture healing).

Only studies written in English and published in indexed, peer-reviewed Journals were reported. No restriction was set on the date of publication.

Selection of Studies and Data Collection

Two independent reviewers assessed the primary studies after excluding the duplicates identified from one or more search databases. Studies were screened based on a two steps assessment. The first step was the assessment of both titles and abstracts of the studies. The unsuitable studies were excluded, and then the second step of the assessment continued with a full-text screening. The eligible studies were then classified as suitable for the systematic review and presented in Table 1. The following data were extracted from each of the eligible studies. The collected data are summarized in Appendix C.

- 1) Study characteristics (first author’s name, year of publication, study design);
- 2) Avian species characteristics (number, species);
- 3) Orthopedic conditions characteristics (involved bone, location, type, severity)
- 4) Intervention characteristics (type of ESF, fracture reduction, removal time, clinical findings, complications);
- 5) Main results of the included studies.

Table 1
Included studies based on the alphabetical order of the first author

Author (year)	Study design	No. of patient	Bird species
Ackermann & Redig (1997)	CS	4	Raptors (Wild)
Arias et al. (2015)	CR	1	Slender-billed Parakeet (Wild)
Bueno et al. (2015)	CS	37	Raptors (Wild, Captive)
Bueno et al. (2019)	CR	2	Raptors (Wild)
Burdeaux & Wade (2018)	CR	1	Snowy owl (Wild)
Carrasco et al. (2017)	CS	35	Pet birds
Folland et al. (2016)	CR	1	Bald eagle (Wild)

Table 1 (continue)

Author (year)	Study design	No. of patient	Bird species
Hatt et al. (2007)	CS	18	Psittacine, Raptor, Passerine (Captive, Pet, Wild)
Hoybergs et al. (2008)	CR	1	Harris's hawk (Captive)
Jones & Redig (2001)	CR	1	Red-tailed hawk (Wild)
Katogiritis et al. (2019)	CR	2	Psittacines (Pet)
Kavanagh (1997)	CR	1	Scarlet macaw (Pet)
Kaya & Özsoy (2017)	CS	19	Chukar partridges and Domestic pigeons (Captive)
Kinney et al. (2015)	CR	1	African sacred ibis (Captive)
Martin et al., (1993)	CS	8	Raptors
Meij et al. (1996)	CS	12	Psittacines, Peacock, Domestic fowl, Racing pigeons (Pet, Captive)
Montgomery et al. (2011)	CR	1	Bald eagle (Wild)
Rahal et al. (2008)	CR	1	Toco toucan (Captive)
Rochat et al. (2005)	CR	1	Bald eagle (Wild)
Rosenthal et al. (1994)	CR	2	Moluccan cockatoo & barn owl
Rui et al. (2017)	CR	1	Rock pigeon (Free flying)
Sample et al. (2008)	CR	1	Whooping crane (Captive)
Vergneau-Grosset et al. (2019)	CS	14	Raptors (Wild)
Vergneau-Grosset et al. (2020)	CS	24	Raptors (Wild)
Van Wettere & Redig (2004)	CR	2	Raptors (Wild)
Yoon et al. (2008b)	CR	1	Great Horned Owl (Wild)
Yoon et al. (2008a)	CS	19	Raptors (Wild)

CR: case report, CS: case series.

RESULTS

Descriptive Statistics of ESF Implants Used

In comparison to mammals, the healing of orthopedic conditions in avian patients requires additional challenges. These challenges are mostly related to thin cortices and low soft tissue support, including blood vessels and nerves. These challenges have made the stabilization of fractures more difficult. Moreover, some features of the fractured bone can pose additional difficulty to the stabilization of avian orthopedic conditions (Helmer & Redig, 2006). For instance, the relatively small medullary cavity of the tibiotarsus is making the fixation of tibiotarsal orthopedic conditions more difficult (Kinney et al., 2015). In this regard, various types of ESF have been developed to provide a practical tool to stabilize the avian orthopedic condition to fulfill the specific need of certain orthopedic conditions. Figure 1 presents the percentage of different types of ESF used in different avian orthopedic conditions. Results showed that tie-in was mainly used for humeral, femoral, and tibiotarsal fractures. For tarsometatarsal and carpometacarpal fractures, ESF type2 was used mainly.

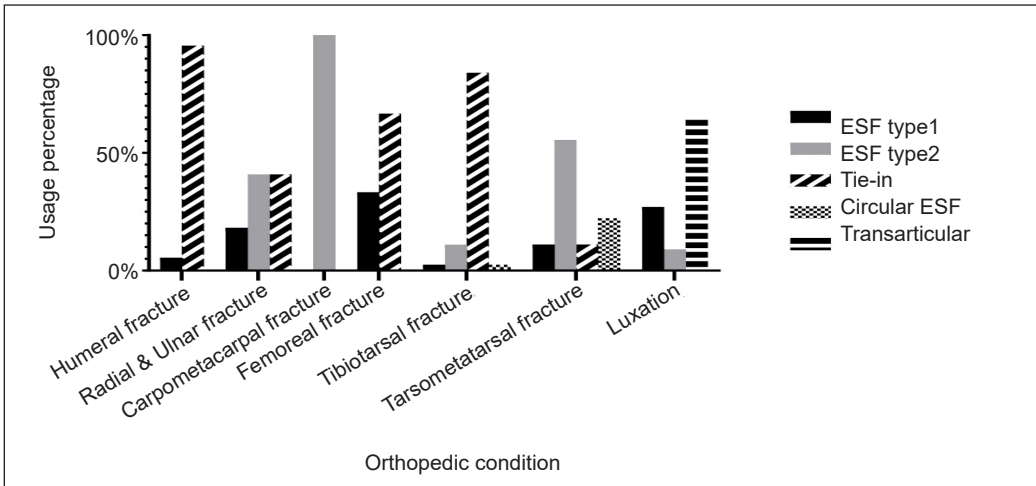


Figure 1. Percentage of different types of ESF used in different avian orthopedic conditions

Transarticular ESF was the main choice to stabilize luxation in the studies. Both type2 and tie-in were equally used to stabilize the fractures for radial and ulnar fractures.

Release Percentage of Raptors

Release percentage can indicate the suitability of each ESF technique for different avian orthopedic cases, especially in injured raptors. The decision on releasing injured raptors into the wild requires a complete healing of the orthopedic condition without any complications and comorbidities. The percentage of the injured raptors released for each type of ESF used to stabilize different orthopedic conditions of raptors can be found in Figure 2. Results

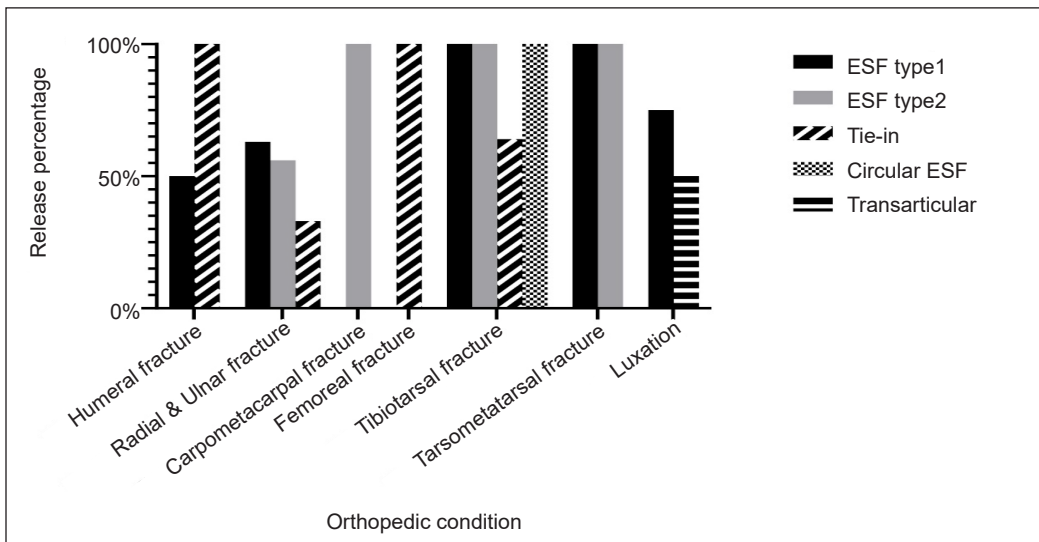


Figure 2. Release percentage of injured raptors with different orthopedic conditions

showed that tie-in ESF for the humeral and femoral fractures led to a more successful release rate of raptors. For carpometacarpal fracture, ESF type 2 had a more successful release rate. For luxation and radial and ulnar fracture, ESF type 1 was more successful. In tarsometatarsal fracture, ESF type 1 and type 2 showed an equal successful release rate of injured raptors. ESF type 1, type 2, and circular ESF had equal success in the release of injured raptors. Falconry techniques can be very useful in flight assessment and recovery of these raptors' flight strength before the injury. These techniques were used in 10% of the raptor cases. The birds recovered their flight potency in all of these cases and were successfully released to the wild.

Required Stabilization Period

One of the key factors in the treatment of avian orthopedic conditions is the period required for the ESF implant to stabilize the fracture or luxation. In other words, the lesser the time required for ESF, the better the stabilization. This period can also indicate the suitability of the ESF technique used. This period started when the ESF implant was employed during the surgery and usually ends when radiography findings approved firm callus bridging at the fracture site. This period is more highlighted for wild raptors, as they need to be released to the wild as soon as possible. Fracture severity, fracture type, and fracture location can influence the ESF implant usage period, especially by looking at this period from the fracture's perspective only. Therefore, these factors affect the type of ESF considered to be used. Table 2 shows the average time required for different ESF types to stabilize different orthopedic conditions. The ESF removal times reported in the studies with negative outcomes were excluded from this calculation.

Table 2
Average time spent for different types of ESF to stabilize different orthopedic conditions

Orthopedic condition	Average time required for ESF (week(s) after surgery)					
	Type 1	Type 2	Tie-in		Circular	Transarticular
			IM	ESF pins		
Load sharing fracture	6	9	5	8	5	-
Non-load sharing fracture	8.5	7	5	6.5	9	-
Open fracture	10	6	5	6.5	7	-
Close fracture	6	8.5	5.5	7.5	8.5	-
Proximal fracture	-	8	6	8	12	-
Midshaft fracture	8	8	5	7	6.5	-
Distal fracture	6	7	3	5	5	-
Osteotomy	9	8	2	5	5	-
Arthrodesis	12	13	-	-	-	-
Luxation	7.5	-	-	-	-	1

Complications of External Fixation

Complications associated with external fixation can delay the removal of the ESF implant, which ultimately may fail in the fracture to heal. These complications can be categorized into major and minor. In major complications, there is a high risk of fracture healing failure. Minor complications, however, cause discomfort for the patients and seldom result in healing failure (Egger, 1991). Failure of apparatus to provide adequate stability, failure of the bone-fixation pin interface, and healing problems of fracture or luxation are considered major complications. On the other hand, minor complications include pin-tract drainage, poor limb use, injury to musculotendon structures, and neurovascular damage (Egger, 1991; Marti & Miller, 1994). Thirty-eight complications were reported among the 166 avian patients with orthopedic conditions (38/166, 22%). Major complications have formed the majority of the 29/38 (76%). These include 21/29 (72%) reports of fracture or luxation healing problems, six reports on the failure of the bone-fixation pin interface, and two reports of failure of the apparatus to provide adequate stability. Forty-two percent of major complications lead to failure in healing. Failure in healing led to 11 cases of euthanasia, three cases of amputation, two cases of significant shortening, and two cases of arthrodesis. In addition, two cases of aspergillosis and one case of plasmodium infestation resulted in the death of patients prior to the healing of the orthopedic condition.

DISCUSSION

This systematic review aimed to summarize and evaluate the use of ESF as the most common stabilizer in the treatment of avian orthopedic conditions. Compared with mammals, treatment of avian orthopedic conditions faces additional challenges. Avian bones have lower soft tissue support, contain a higher proportion of hydroxyapatite, and have thinner and more brittle cortices (Bennett & Kuzma, 1992; Degernes et al., 1998). External skeletal fixators can provide fracture reduction without impairing the vascularization of the fracture site (Bush et al., 1976). Detailed information on different techniques of ESF and their suitability to stabilize different types of fractures has been reported (Harcourt-Brown, 2002; Orosz, 2002). Apart from summarizing the frequency of each ESF technique used to stabilize different orthopedic conditions in a larger number of cases, this paper also provides additional information on two major factors involved in ESF; required fixation time and complications. One of the main variables that should be considered when choosing the proper type of ESF is fractured bone. For instance, humeral fractures are prone to comminuted fractures and hard to stabilize (Bennett & Kuzma, 1992; MacCoy, 1992). Consistent results were observed in the data in which the majority (80%) of the humeral fractures were comminuted, and all the healed humeral fractures were stabilized by tie-in ESF. Fractures of tarsometatarsus also inhere additional challenges mainly related to the small medullary cavity and being hard to stabilize (Helmer & Redig, 2006). Six

tarsometatarsal fractures were stabilized with either type 2 or tie-in ESF, and most of the tie-in cases had major or minor complications causing delayed healing or amputation.

This might indicate the unsuitability of tie-in ESF for stabilization of tarsometatarsal fractures. On the other hand, Circular ESF has been deemed a more proper fixation method for tarsometatarsal fractures. Circular ESF can also provide distraction osteogenesis, especially in cases where tibiotarsal shortening happened due to the malunion of the two fracture ends stabilized by unsuitable fixators (Bueno et al., 2019). Speaking of bones with a relatively small medullary cavity, radial and ulnar (antebrachial) fractures are the most complex challenges in avian orthopedics. These bones are always under torsional forces, making them more susceptible to complex fractures than other forelimb bones (De Margerie, 2002). Since these bones play a key role in the circumduction of wings, any impairment in the healing of antebrachial fractures can prevent the pronation and supination movements of the wing required for adequate flight (Beaufriere, 2009). Tie-in and type 1 ESF techniques are the recommended fixation methods for antebrachial fractures (Orosz, 2002). This study showed that tie-in ESF was slightly more preferable than type 1 ESF. Synostosis is a common sequela to antebrachial fractures. This complication is common for external coaptation of antebrachial fractures and can reduce the flight capability of recovered birds (Orosz et al., 1992). Two cases of synostosis were reported in the included studies.

Consistent findings can be seen in the successful release of raptors statistics, whereby the fracture of large bones requires a higher stabilization force, which can be found in tie-in. However, tie-in might be less suitable for the bones with a small medullary cavity. It can be noticed by looking at the release percentage of raptors according to which higher release was seen when type 1 ESF was used for antebrachial fractures. Various factors such as complications, comorbidities, captivity stress, and species specificity can cause failure to release raptors into the wild (Bueno et al., 2015; Vergneau-Grosset et al., 2019). Altogether, 31 complications and 12 cases with comorbidities were reported for the injured raptors. Thirteen cases were recovered from complications and comorbidities, but the rest of the birds were either euthanized or became captive for various purposes. Species distribution is the main factor in the frequent representation of a species. However, it is notable that bald eagle, great horned owl, and red-tailed hawk were the most common admitted raptors.

The severity and type of fracture can also affect bone healing substantially. In this regard, the average time required for each type of ESF to treat different kinds of orthopedic conditions with different severity and type can be practical factors to show each ESF technique's suitability. A previous study found that none of the severity and type of fracture were significantly affected the required time for each type of ESF to successfully stabilize the fracture (Bueno et al., 2015). Clinical trials showed that less than six weeks is required for the type 1 ESF to stabilize the healing of the experimental transverse fractures of

ulna in pigeon models (Hatt et al., 2007; Tunio et al., 2014). Using a lightweight external fixator in a system called Fixateur Externe du Service de Santé des Armées (FESSA) can reduce the fixation time to 4 weeks in the same type of fracture using both types 1 and tie-in ESF (Hatt et al., 2007). The adjustable feature of FESSA allows veterinarians to create numerous construct configurations. For example, one uses hinges to connect two FESSA tubes as a transarticular fixator to stabilize the luxation. This system can fix the joint at a desirable angle and makes physical therapy possible without removing the fixator (Azmanis et al., 2014).

When it comes to extremely complex bone fractures in which there is a need to replace bone defects, common orthopedic techniques alone might not provide a good prognosis as the bone itself can only regenerate the small fracture defects. However, different techniques of bone grafting can provide a practical way to treat bone defects in animal orthopedic practices (Nunamaker & Rhinelander, 1985). Osteoinductive, osteoconductive, and osteogenic properties of bone grafts will allow the fractured bone to regenerate the bone defects feasibly.²² Various techniques of bone grafting have been introduced in avian orthopedics. These include the use of callus graft, cortical graft, bone morphogenetic proteins, bone marrow, and hydroxyapatite (HA) (MacCoy & Haschek, 1988; Jones & Redig, 2001; Sample et al., 2008; Sanaei et al., 2011; Sanaei et al., 2015; Tunio et al., 2015). Most of these studies used an external skeletal fixator (ESF) as the stabilizer to expedite fracture healing. Four of the included studies used bone grafting techniques, two of which are case reports, and the other two are clinical control trials.

Case reports were used autogenous callus and recombinant human bone morphogenetic protein-2 to treat the humeral bone defects in a red-tailed hawk and a whooping crane, respectively (Jones & Redig, 2001; Sample et al., 2008). The red-tailed hawk had a close midshaft comminuted fracture, and healing was achieved within five weeks after surgery-based radiography findings. On the other hand, the whooping crane suffered an open proximal comminuted fracture that healed within fourteen weeks after surgery. Autogenous bone grafts are considered the gold treatment for repairing bone defects. However, alternative bone graft materials are needed in avian patients due to the limitation of autogenous bone grafts (Bennett & Kuzma, 1992; Jalila et al., 2004). In a recent study, it has been found that the allogenic tubular demineralized bone marrow, along with the application of tie-in ESF, can be a promising alternative to autogenous bone grafts in the treatment of the critical bone defect of the ulna (Sanaei et al., 2015).

CONCLUSION

The implications of the summarized data suggest that each avian orthopedic condition requires a specific way of fixation. In the bigger picture, the involved bone or joint, type of fracture or luxation, and the fracture location are the main factors that should be

considered when an ESF technique is decided to be employed. This review also provides guiding principles for choosing a suitable ESF, highlighted more when dealing with the raptor's emergency orthopedic cases. However, this systematic review has several important limitations. These limitations pertain to the incompleteness of the outcome. Complications and the implementations taken were underreported. Several reports lacked ESF implant removal time, and some reports lacked sufficient radiographic assessments before and after the removal of ESF implants. Some studies did not report whether the recovered birds were returned to their formal status. Given such incompleteness of data, this review cannot suggest the best ESF technique for different avian orthopedic conditions, making this review less conclusive than it had hoped. However, it provides clinicians with guiding principles for choosing suitable ESF techniques and the ESF-related complications they should know.

ACKNOWLEDGEMENT

The authors give special thanks to Dr. Claire Vergneau-Grosset for providing supplementary data on her works and her valuable comments and guidance. In addition, the authors are grateful to Dr. Jean-Michel Hatt and Dr. Irene Bueno for sharing the supplementary data of their works.

REFERENCES

- Ackermann, J., & Redig, P. (1997). Surgical repair of elbow luxation in raptors. *Journal of Avian Medicine and Surgery*, 11(4), 247-254.
- Arias, J. I., Beato, C., & Espinoza, A. (2015). Epoxy putty external skeletal fixation in a tibiotarsal fracture of a wild choroy parakeet (*Enicognathus leptorhynchus*). *Arquivo Brasileiro de Medicina Veterinária e Zootecnia*, 67, 671-678. <https://doi.org/10.1590/1678-4162-7474>
- Azmanis, P. N., Voss, K., & Hatt, J. M. (2014). Evaluation of short-term outcomes of experimental stifle luxation in feral pigeons (*Columba livia domestica*) treated with a hinged transarticular external skeletal fixator and physical therapy. *International Journal of Applied Research in Veterinary Medicine*, 12(2), 157-166.
- Beaufre, H. (2009). A review of biomechanic and aerodynamic considerations of the avian thoracic limb. *Journal of Avian Medicine and Surgery*, 23(3), 173-185. <https://doi.org/10.1647/2007-023.1>
- Bennett, R. A. (1994). Neurology. In B. W. Ritchie, G. J. Harrison, & L. R. Harrison (Eds.), *Avian Medicine: Principles and Application* (pp. 721-747). Wingers Publishing.
- Bennett, R. A., & Kuzma, A. B. (1992). Fracture management in birds. *Journal of Zoo and Wildlife Medicine*, 23(1), 5-38.
- Bueno, I., Anderson, G., Willette, M., Redig, P. T., & Ponder, J. (2019). Distraction osteogenesis in two wild raptors. *Journal of Avian Medicine and Surgery*, 33(4), 427-436. <https://doi.org/10.1647/2018-384>

- Bueno, I., Redig, P. T., & Rendahl, A. K. (2015). External skeletal fixator intramedullary pin tie-in for the repair of tibiotarsal fractures in raptors: 37 cases (1995-2011). *Journal of the American Veterinary Medical Association*, 247(10), 1154-1160. <https://doi.org/10.2460/javma.247.10.1154>
- Burdeaux, R. R., & Wade, L. (2018). Successful management of open, contaminated metacarpal fractures in an adult snowy owl (*Bubo scandiacus*) with a minimal type II external skeletal fixator. *Journal of Avian Medicine and Surgery*, 32(3), 210-216. <https://doi.org/10.1647/2017-280>
- Bush, M., Montali, R. J., Novak, G. R., & James, A. E. (1976). The healing of avian fractures: A histological xeroradiographic study. *Journal of the American Animal Hospital Association*, 12(6), 768-773.
- Buttle, E. P. (2004). Concomitant leg injuries in raptors with wing damage: To the editor. *Journal of the South African Veterinary Association*, 75(4), Article 154. <https://doi.org/10.4102/jsava.v75i4.473>
- Carrasco, D. C. (2019). Fracture management in avian species. *Veterinary Clinics: Exotic Animal Practice*, 22(2), 223-238. <https://doi.org/10.1016/j.cvex.2019.02.002>
- Carrasco, D. C., Shimizu, N., Zoller, G., Huynh, M., & Forbes, N. A. (2017, March 25-29). Retrospective study on 35 tibiotarsal fracture repairs with external skeletal fixator-intramedullary pin tie-in in pet birds. In *3rd International Conference on Avian Herpetological and Exotic Mammal Medicine (ICARE)*. Venice, Italy.
- De Margerie, E. (2002). Lamellar bone as an adaptation to torsional loads in flapping flight. *Journal of Anatomy*, 201(6), 521-526. <https://doi.org/10.1046/j.1469-7580.2002.00118.x>
- Degernes, L. A., Roe, S. C., & Abrams Jr, C. F. (1998). Holding power of different pin designs and pin insertion methods in avian cortical bone. *Veterinary Surgery*, 27(4), 301-306. <https://doi.org/10.1111/j.1532-950X.1998.tb00131.x>
- Egger, E. L. (1991). Complications of external fixation: A problem-oriented approach. *Veterinary Clinics of North America: Small Animal Practice*, 21(4), 705-733. [https://doi.org/10.1016/S0195-5616\(91\)50080-2](https://doi.org/10.1016/S0195-5616(91)50080-2)
- Fix, A. S., & Barrows, S. Z. (1990). Raptors rehabilitated in Iowa during 1986 and 1987: A retrospective study. *Journal of Wildlife Diseases*, 26(1), 18-21. <https://doi.org/10.7589/0090-3558-26.1.18>
- Folland, D. W., Echols, M. S., & Wallace, M. (2016). Elbow arthrodesis in a bald eagle (*Haliaeetus leucocephalus*). *Journal of Exotic Pet Medicine*, 25(3), 203-207. <https://doi.org/10.1053/j.jepm.2016.05.003>
- Harcourt-Brown, N. H. (2002). Orthopedic conditions that affect the avian pelvic limb. *The Veterinary Clinics of North America. Exotic Animal Practice*, 5(1), 49-81. [https://doi.org/10.1016/S1094-9194\(03\)00046-X](https://doi.org/10.1016/S1094-9194(03)00046-X)
- Hatt, J. M., Christen, C., & Sandmeier, P. (2007). Clinical application of an external fixator in the repair of bone fractures in 28 birds. *Veterinary Record*, 160(6), 188-194. <https://doi.org/10.1136/vr.160.6.188>
- Helmer, P., & Redig, P. T. (2006). Surgical resolution of orthopedic disorders. In J. G. Harrison, & L. T. Lightfoot (Eds.), *Clinical Avian Medicine* (pp. 761-773). Spix Publishing.
- Hoybergs, Y., Bosmans, T., Risselada, M., Van Caelenberg, A., & Polis, I. (2008). General anesthesia for the surgical repair of a tarsometatarsal fracture in a Harris's Hawk (*Parabuteo unicinctus*). *Vlaams Diergeneeskundig Tijdschrift*, 77(5), 309-314.
- Jalila, A., Redig, P. T., Wallace, L. J., Ogema, T. R., Bechtold, J. E., & Kidder, L. (2004). The effect of chicken, pigeon, and turkey demineralized bone matrix (DBM) implanted in ulnar defects fixed with

- the intramedullary-external skeletal fixator (IM-ESF) tie-in in pigeons (*Columba livia*): Histological evaluations. *The Medical Journal of Malaysia*, 59, 125-126.
- Jones, R., & Redig, P. T. (2001). Autogenous callus for repair of a humeral cortical defect in a red-tailed hawk (*Buteo jamaicensis*). *Journal of Avian Medicine and Surgery*, 15(4), 302-309. [https://doi.org/10.1647/1082-6742\(2001\)015\[0302:ACFROA\]2.0.CO;2](https://doi.org/10.1647/1082-6742(2001)015[0302:ACFROA]2.0.CO;2)
- Katogiritis, A., Barry, S. L., & Finch, N. (2019). Key ring fixator: A novel external fixation technique for avian long bone stabilization. *Journal of Avian Medicine and Surgery*, 33(2), 161-170. <https://doi.org/10.1647/2018-355>
- Kavanagh, M. (1997). Tibiotarsal fracture repair in a scarlet macaw using external skeletal fixation. *Journal of Small Animal Practice*, 38(7), 296-298. <https://doi.org/10.1111/j.1748-5827.1997.tb03469.x>
- Kaya, D. A., & Özsoy, S. (2017). Repair of tibiotarsal rotation in 7 chukar partridges (*Alectoris chukar*) and 12 domestic pigeons (*Columba livia domestica*) with type-2 external skeletal fixator intramedullary pin tie-in. *Journal of Avian Medicine and Surgery*, 31(3), 206-212. <https://doi.org/10.1647/2016-160>
- Kinney, M. E., Gorse, M. J., & Anderson, M. A. (2015). Circular external fixator placement for repair of an open distal tarsometatarsal fracture in an African sacred ibis (*Threskiornis aethiopicus*). *Journal of Zoo and Wildlife Medicine*, 46(4), 957-960. <https://doi.org/10.1638/2015-0154.1>
- Liberati, A., Altman, D. G., Tetzlaff, J., Mulrow, C., Gøtzsche, P. C., Ioannidis, J. P. A., Clarke, M., Devereaux, P. J., Kleijnen, J., & Moher, D. (2009). The PRISMA statement for reporting systematic reviews and meta-analyses of studies that evaluate health care interventions: Explanation and elaboration. *Journal of Clinical Epidemiology*, 62(10), e1-e34. <https://doi.org/10.1016/j.jclinepi.2009.06.006>
- MacCoy, D. M. (1992). Treatment of fractures in avian species. *Veterinary Clinics of North America: Small Animal Practice*, 22(1), 225-238. [https://doi.org/10.1016/S0195-5616\(92\)50016-X](https://doi.org/10.1016/S0195-5616(92)50016-X)
- MacCoy, D. M., & Haschek, W. M. (1988). Healing of transverse humeral fractures in pigeons treated with ethylene oxide-sterilized, dry-stored, onlay cortical xenografts and allografts. *American Journal of Veterinary Research*, 49(1), 106-111.
- Marti, J. M., & Miller, A. (1994). Delimitation of safe corridors for the insertion of external fixator pins in the dog 1: Hindlimb. *Journal of Small Animal Practice*, 35(1), 16-23. <https://doi.org/10.1111/j.1748-5827.1994.tb03576.x>
- Martin, H., Bruecker, K., Herrick, D., & Scherpelz, J. (1993). Elbow luxation in raptors: A review of eight cases. In P. T. Redig, J. E. Cooper, J. D. Remple, & D. B. Hunter (Eds.), *Raptor Biomedicine* (pp. 199-206). University of Minnesota Press.
- Meij, B. P., Hazewinkel, H. A., & Westerhof, I. (1996). Treatment of fractures and angular limb deformities of the tibiotarsus in birds by type II external skeletal fixation. *Journal of Avian Medicine and Surgery*, 10(3), 153-162.
- Moher, D., Liberati, A., Tetzlaff, J., Altman, D. G., & Prisma Group. (2009). Preferred reporting items for systematic reviews and meta-analyses: The PRISMA statement. *PLoS Medicine*, 6(7), Article e1000097. <https://doi.org/10.7326/0003-4819-151-4-200908180-00135>

- Montgomery, R. D., Crandall, E., & Bellah, J. R. (2011). Use of a locking compression plate as an external fixator for repair of a tarsometatarsal fracture in a bald eagle (*Haliaeetus leucocephalus*). *Journal of Avian Medicine and Surgery*, 25(2), 119-125. <https://doi.org/10.1647/2009-016.1>
- Nunamaker, D. M., & Rhinelander, F. W. (1985). Bone grafting. In C. D. Newton, & D. M. Nunamaker (Eds.), *Textbook of Small Animal Orthopaedics* (pp. 261-286). JB Lippincott.
- Orosz, S. E. (2002). Clinical considerations of the thoracic limb. *The Veterinary Clinics of North America. Exotic Animal Practice*, 5(1), 31-48. [https://doi.org/10.1016/S1094-9194\(03\)00045-8](https://doi.org/10.1016/S1094-9194(03)00045-8)
- Orosz, S. E., Ensley, P. K., & Haynes C. J. (1992). Considerations for avian surgery. In S. E. Orosz, P. K. Ensley, & C. J. Haynes (Eds.), *Avian Surgical Anatomy: Thoracic and Pelvic Limbs* (pp. 111-120). WB Saunders.
- Ponder, J. B., & Redig, P. (2016). Orthopedics. In B. Speers (Ed.), *Current Therapy in Avian Medicine and Surgery* (pp. 657-667). Elsevier Health Sciences.
- Rahal, S. C., Teixeira, C. R., Pereira-Junior, O. C., Vulcano, L. C., Aguiar, A. J., & Rassy, F. B. (2008). Two surgical approaches to fracture malunion repair. *Journal of Avian Medicine and Surgery*, 22(4), 323-330. <https://doi.org/10.1647/2007-058.1>
- Redig, P. T., & Ponder, J. (2016). Orthopedic surgery. In J. Samour (Ed.), *Avian Medicine* (pp. 312-358). Elsevier. <https://doi.org/10.1016/B978-0-7234-3832-8.00012-2>
- Rochat, M. C., Hoover, J. P., & DiGesualdo, C. L. (2005). Repair of a tibiotarsal varus malunion in a bald eagle (*Haliaeetus leucocephalus*) with a type 1A hybrid external skeletal fixator. *Journal of Avian Medicine and Surgery*, 19(2), 121-129. <https://doi.org/10.1647/2004-003>
- Rosenthal, K., Hillyer, E., & Mathiessen, D. (1994). Stifle luxation repair in a *Moluccan cockatoo* and a barn owl. *Journal of the Association of Avian Veterinarians*, 8(4), 173-178. <https://doi.org/10.2307/30135077>
- Rui, L. A., Viana, D. C., Dora, A. B., & Fratini, P. (2017). External fixation to correct tarsal-metatarsal fracture in rock pigeon (*Columba livia*). *Revista Ceres*, 64, 25-30. <https://doi.org/10.1590/0034-737x201764010004>
- Sample, S., Cole, G., Paul-Murphy, J., Hartup, B. K., Clyde, V., Seeherman, H. J., & Schaefer, S. (2008). Clinical use of recombinant human bone morphogenic protein-2 in a Whooping Crane (*Grus americana*). *Veterinary Surgery*, 37(6), 552-557. <https://doi.org/10.1111/j.1532-950X.2008.00419.x>
- Sanaei, M. R., Abu, J., Nazari, M., Faiz, N. M., Bakar, M. Z. A., & Allaudin, Z. N. (2011). Heterotopic implantation of autologous bone marrow in rock pigeons (*Columba livia*): Possible applications in avian bone grafting. *Journal of Avian Medicine and Surgery*, 25(4), 247-253. <https://doi.org/10.1647/2010-035.1>
- Sanaei, R., Abu, J., Nazari, M., Zuki, M. A., & Allaudin, Z. N. (2015). Evaluation of osteogenic potentials of avian demineralized bone matrix in the healing of osseous defects in pigeons. *Veterinary Surgery*, 44(5), 603-612. <https://doi.org/10.1111/vsu.12292>
- Tully Jr, T. N. (2002). Basic avian bone growth and healing. *The Veterinary Clinics of North America. Exotic Animal Practice*, 5(1), 23-30. [https://doi.org/10.1016/S1094-9194\(03\)00044-6](https://doi.org/10.1016/S1094-9194(03)00044-6)
- Tunio, A., Jalila, A., & Goh, Y. M. (2015). Histologic evaluation of critical size defect healing with natural and synthetic bone grafts in the pigeon (*Columba livia*) ulna. *Journal of Avian Medicine and Surgery*, 29(2), 106-113. <https://doi.org/10.1647/2013-047>

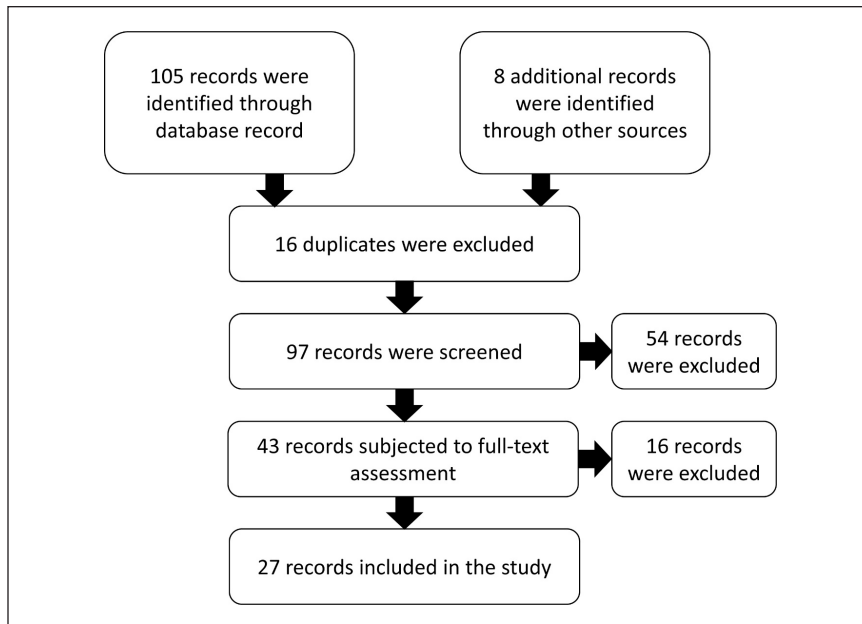
- Tunio, A., Jalila, A., Meng, C. Y., & Shameha, I. (2014). Experimental fracture healing with external skeletal fixation in a pigeon ulna model. *Journal of Advanced Veterinary and Animal Research*, 1(2), 58-64. <https://doi.org/10.5455/javar.2014.a14>
- Van Wettere, A. J., & Redig, P. T. (2004). Arthrodesis as a treatment for metacarpophalangeal joint luxation in 2 raptors. *Journal of Avian Medicine and Surgery*, 18(1), 23-29. <https://doi.org/10.1647/2003-002>
- Van Wettere, A. J., Redig, P. T., Wallace, L. J., Bourgeault, C. A., & Bechtold, J. E. (2009). Mechanical evaluation of external skeletal fixator-intramedullary pin tie-in configurations applied to cadaveral humeri from red-tailed hawks (*Buteo jamaicensis*). *Journal of Avian Medicine and Surgery*, 23(4), 277-285. <https://doi.org/10.1647/1082-6742-23.4.277>
- Vergneau-Grosset, C., Dubé, C., Fitzgerald, G., & Lair, S. (2020). Characteristics of antebrachial fractures associated with a successful outcome among free-ranging birds of prey that received treatment in a rehabilitation program. *Journal of the American Veterinary Medical Association*, 256(5), 580-589. <https://doi.org/10.2460/javma.256.5.580>
- Vergneau-Grosset, C., Kapatkin, A. S., Paul-Murphy, J., Guzman, D. S. M., & Hawkins, M. G. (2019). Release rates and complications for birds of prey with antebrachial fractures at a veterinary teaching hospital. *Journal of Avian Medicine and Surgery*, 33(4), 388-397. <https://doi.org/10.1647/2018-394>
- Yoon, H. Y., Fox, D. B., & Jeong, S. W. (2008). Long bone fractures in raptors: 28 cases (2004-2007). *Journal of Veterinary Clinics*, 25(3), 215-217.
- Yoon, H. Y., Fox, D. B., & Jeong, S. W. (2008). Tibiotarsal and ulnar fracture repair in a great horned owl (*Bubo virginianus*). *Journal of Veterinary Clinics*, 25(3), 218-220.

APPENDIX A

The keywords and how Boolean characters (AND, OR) are used for the electronic search. (((("external skeletal fixator") OR ("ESF") OR ("external fixator") OR ("external fixation") OR ("external skeletal") OR ("tie-in") OR ("hybrid external fixator") OR ("hybrid external fixation"))) AND (("fracture") OR ("luxation") OR ("bone") OR ("bone fracture") OR ("osteosynthesis") OR ("osteogenic") OR ("osseous defects") OR ("tarsometatarsal") OR ("tibiotarsal") OR ("femoral") OR ("humeral") OR ("rotation") OR ("dislocation") OR ("arthrodesis") OR ("radial") OR ("ulnar") OR ("antebrachial"))) AND (("avian") OR ("bird") OR ("pigeon") OR ("goose") OR ("raptor") OR ("exotic bird") OR ("owl") OR ("eagle") OR ("duck") OR ("chicken") OR ("turkey") OR ("poultry") OR ("fowl") OR ("hawk") OR ("partridges") OR ("macaw") OR ("pheasant") OR ("parrot") OR ("psittacine") OR ("pet bird") OR ("wild bird") OR ("hobby bird") OR ("game bird") OR ("birds of prey") OR ("falcon") OR ("kestrel")))

APPENDIX B

PRISMA flow diagram to select the included studies.



APPENDIX C

Data summary table

Author	Year	Species	Orthopedic condition	ESF type	Complications	Radiography & clinical findings	Remarks
Van Wetteere & Redig	2004	Prairie falcon	Closed metacarpophalangeal joint luxation	Type 1	No complications	Week 4: periosteal and medullary bridging. Week 6: bridging was complete, and the distal external skeletal fixator pin was loose).	19 weeks later, the bird was released into the wild (falconry techniques were used).
		Great horned owl	Open metacarpophalangeal joint luxation	Type 1	No complications	Week 4: periosteal and medullary fusion. Week 6: periosteal bridging. Week 9: complete healing.	17 weeks later, the bird was released into the wild (falconry techniques were used).
Kinney et al.	2015	African sacred ibis	Open distal comminuted tarsometatarsal fracture	Circular ESF			58 days after fracture diagnosis, the bird was recovered completely.
Sample et al.	2008	Whooping crane	Open proximal comminuted humeral fracture	Tie-in	Aspergillosis (itraconazole was administered)	Week 4: callus formation. Week 8: callus bridging. Week 11: further callus remodeling. Week 14: both cortices re-established.	Recombinant human bone morphogenic protein-2 was used.
Folland et al.	2016	Bald eagle	Elbow joint malfunctioning (possibly due to the osteomyelitis developed during previous humeral fracture healing) (arthrodesis)	Type 1 (the first attempt failed, then modified with lag screws)	Osteomyelitis, severe wing drooping	Week 9: significant bony fusion	The second attempt for the arthrodesis was successful
Arias et al.	2015	Slender-billed parakeet	Closed distal transverse tibiotarsal fracture	Type 1		Week 4: initial callus formation with the osseous union. Week 6: mature and well-organized callus.	Eight weeks after surgery, the bird was released
Rui et al.	2017	Rock pigeon	Open midshaft tarsometatarsal fracture	Type 2		Day 15: no presence of callus or disappearance of fracture. Day 60: bone healing was confirmed	

Data summary table (*continue*)

Author	Year	Species	Orthopedic condition	ESF type	Complications	Radiography & clinical findings	Remarks
Bueno et al.	2015	American kestrel			Broken ESF pin at 14 days. The bird was healed and released		
		Bald eagle (x11)					
		Barred owl					
		Broad-winged hawk (x2)					
		Eastern screech owl					
		Great gray owl (x2)	Tibiotarsal Fracture (35 closed, 2 open)	Tie-in	ESF pin loosening in one case (the bird was euthanized).	Week 2-3: sufficient callus was formed (IM pin was removed). Week 4-5: continuous callus formation and weight-bearing on the affected limb (ESF implant was removed).	20/34 birds were healed completely and returned to their former status. Five fracture healing complications. One case of aspergillosis and one case of plasmodium died.
		Great horned owl (x6)					
		Harris hawk					
		Osprey					
		Peregrine falcon (x3)					
Red-tailed hawk (x7)				ESF pin loosening in one case (the bird was completely healed and released).			
		Turkey vulture					
Hoybergs et al.	2008	Harris's hawk	Open midshaft transverse tarsometatarsal fracture	Type 2	Osteolysis	Week 6: good healing with low and medium osteolysis around the pins.	Osteolysis was cured, and the fracture was healed.

Data summary table (*continue*)

Author	Year	Species	Orthopedic condition	ESF type	Complications	Radiography & clinical findings	Remarks
Katogiritis et al.	2019	Amazon parrot	Open comminuted midshaft tarsometatarsal fracture		Slight shortening	One month: bridging callus formation. Two months: Progressive osseous bridging & healing of the fracture line.	Both tarsometatarsi had a fracture. The left one was treated with coaptation and lost three fingers. The right one got circular ESF. Both fractures healed.
		Catalina macaw	Closed oblique proximal tibiotarsal fracture	Circular ESF	Slight shortening	Day 1: poor apposition of the fracture ends & misalignment of fragments. Week 12: healed fracture & slight shortening of the left tibiotarsus	
Rochat et al.	2005	Bald eagle	Malunion in tibiotarsus (osteotomy)	Type 1 hybrid (4/circular)	Fracture in ulna	Day 27: pins were stable, and healing progress was good. Day 47: good callus formation. Day 63: osteotomy healed, and ESF removed.	Falconry techniques were used.
Kaya & Özsoy	2017	Chukar partridges (x7) Domestic pigeons (x12)	Tibiotarsal rotation (osteotomy)	Tie-in	No complications	Day 22: sufficient callus formation.	The mean time for complete recovery was 46 and 47 days for pigeons and partridges, respectively.
Burdeaux & Wade	2018	Snowy owl	Open transverse midshaft Metacarpal fracture	Type 2 (minimal): 2/2 on one side 1/1 on the other side	Synostosis	Day 25: callus formation. Day 42: periosteal callus at the fracture site and no sign of osteomyelitis.	Severe feather louse infestation. Delayed skin closure (day 25). The bird was recaptured in poor body condition. The birds were maintained and released again.
Ackermann & Redig	1997	Long-eared owl		Transarticular ESF	Aspergillosis		Luxation healed, but the bird died two weeks after removal of ESF due to severe aspergillosis.
		Sharp-shinned hawk	Closed elbow luxation	Transarticular ESF	low motion range of the joint		Luxation healed, but its extension was not enough for optimum flight (the bird was not released).

Data summary table (continue)

Author	Year	Species	Orthopedic condition	ESF type	Complications	Radiography & clinical findings	Remarks
		Peregrine falcon		Transarticular ESF	No complications		The bird was released into the wild after falconry training.
		Eastern screech owl		Transarticular ESF	No complications		Removing the ESF caused a transverse fracture in the ulna. The bird was released into the wild two weeks after the removal of ESF.
Kavanagh	1997	Scarlet macaw	Close transverse proximal tibiotarsal fracture	Type 2 (2/2)		Week 6: callus bridging. Week 11: callus remodeling with the osseous union.	The bird had full use of the limb.
		Hyacinth macaw	Closed transverse midshaft tibiotarsal fracture		No complications		
		Blue and gold macaw	Closed transverse midshaft tibiotarsal fracture		No complications		
		Blue and gold macaw	Closed transverse midshaft tibiotarsal fracture	Type 2 (2/2)	No complications		
		Sulfur-crested cockatoo	Closed spiral midshaft tibiotarsal fracture		No complications		
		African grey parrot	Closed transverse midshaft tibiotarsal fracture		No complications		
		Peacock	Closed comminuted proximal tibiotarsal fracture	Type 2 (3/3)	No complications		
		Domestic fowl	Closed comminuted distal tibiotarsal fracture	Type 2 (2/2)	No complications		
		Racing pigeon	Closed comminuted proximal tibiotarsal fracture	Type 2 (1/2)	Malunion		The fracture was not healed (the bird was euthanized)

Data summary table (*continue*)

Author	Year	Species	Orthopedic condition	ESF type	Complications	Radiography & clinical findings	Remarks
		African grey parrot	Tibiotarsal angular deformity (osteotomy)		No complications		
		Racing pigeon	Tibiotarsal angular deformity (osteotomy)	Type 2 (2/2)	Malunion		The deformity was not healed
		African grey parrot	Tibiotarsal angular deformity (arthrodesis)		No complications		
		Amazon parrot	Tibiotarsal angular deformity (arthrodesis)		No complications		
Rahal et al.	2008	Toco toucan	Tarsometatarsal malunion (osteotomy)	2/2 type 2	Pin tract drainage	Day 15: periosteal callus formation. Day 62: healing of the osteotomy.	
Montgomery et al.	2011	Bald eagle	Open comminuted midshaft tarsometatarsal fracture	3/3 type 1	Pin loosening		falconry techniques were used
Jones & Redig	2001	Red-tailed hawk	Closed comminuted midshaft humeral fracture	Tie-in		Week 2: increase the defect's radiodensity at the fracture site and incorporate the graft material into the callus. Week 3: periosteal, intercortical, and medullary bridging was evident radiographically. Week 5: bridging was complete, and remodeling was evident.	The humerus had a defect: autologous callus was used to fill the defect (falconry techniques).
Yoon et al.	2008b	Great Horned Owl	Close comminuted midshaft tibiotarsus & ulnar fracture	Tie-in	No complications	Week 6: smooth callus formation. Week 13: bridging callus was formed over cortices of the fracture area.	
Yoon et al.	2008a	Raptor species (x19)	Humeral fracture (x12) Tibiotarsal fracture (x4) Ulnar fracture (x2) Femoral fracture	Tie-in	No complications		All the birds were released or returned to their former status.
Vergneau-Grosset et al.	2019	Raptor species	Ulnar fracture (x6)	Type 1	Osteomyelitis (one case) Malunion (two cases)		Eight of 14 birds were released.

Data summary table (continue)

Author	Year	Species	Orthopedic condition	ESF type	Complications	Radiography & clinical findings	Remarks
		Peregrine falcon	ulnar	Tie-in	Osteomyelitis (one case) Malunion (two cases)		Eight of 14 birds were released.
			ulnar & radial (x2)	Tie in & IM			
			ulnar & radial	Tie in & type 1			
			ulnar & radial (x2)	Tie-in			
			ulnar & radial	Type 1			
			ulnar	Type 1			
Bueno et al.	2019	Great horned owl	Open distal oblique tibiotarsal fracture. Shortening happened (osteotomy to distract osteogenesis)	Tie-in (shortening happened). Circular ESF (distract osteogenesis).	Shortening, pododermatitis		falconry techniques were used
			Closed fracture midshaft tibiotarsal fracture	Type I (shortening happened). Circular ESF (distract osteogenesis).	Shortening, malunion		
Hatt et al.	2007	Blue-fronted amazon	Closed comminuted midshaft humeral fracture	Tie-in	IM pin loosening		Delayed healing
			Cockatiel	Closed comminuted midshaft humeral fracture	Tie-in		
		Wild-caught hobby	Open comminuted midshaft humeral fracture	Tie-in	No complication		
			Wild-caught tawny owl	Open comminuted midshaft ulnar & radial fracture	Type 1		
		Wild-caught tawny owl	Open comminuted midshaft ulnar & radial fracture	Type 1	No complication		

Data summary table (continue)

Author	Year	Species	Orthopedic condition	ESF type	Complications	Radiography & clinical findings	Remarks
		Grey parrot	Open comminuted proximal ulnar & radial fracture	Type 1	Non-union		Amputation
		Grey parrot	Closed comminuted midshaft femoral fracture	Tie-in	No complication		
		Wild-caught red kite	Closed comminuted midshaft femoral fracture	Type 1	Minor instability		
		Grey parrot	Tibiotarsal deformity (osteotomy)	Type 2	No complication		
		Goshawk	Closed proximal oblique tibiotarsal fracture	Type 2	No complication		
		Hawk-headed parrot	Closed distal oblique tibiotarsal fracture	Type 2	No complication		
		Grey parrot	Closed distal oblique tibiotarsal fracture	Type 2	No complication		
		White cockatoo	Closed comminuted midshaft tibiotarsal fracture	Tie-in	No complication		
		Grey parrot	Closed comminuted midshaft tibiotarsal fracture	Type 1	Slow callus formation		Delayed healing
		Blue-fronted amazon	Closed transverse midshaft tibiotarsal fracture	Type 2	Malunion		Amputation
		Bali starling	Open simple midshaft tarsometatarsal fracture	Type 2	Osteomyelitis, soft tissue infection		Amputation
		Bodin's amazon	Open simple distal tarsometatarsal fracture	Tie-in	Non-union		Amputation
		Wild-caught barn owl	Open comminuted midshaft tarsometatarsus	Type 2	Osteolysis around one pin		

Data summary table (*continue*)

Author	Year	Species	Orthopedic condition	ESF type	Complications	Radiography & clinical findings	Remarks	
Vergneau-Grosset et al.	2020	Merlin (x3)	Open transverse midshaft radial & ulnar fracture	Type 1				
			Closed comminuted radial & ulnar fracture	Tie-in			Ulnar fracture healed only (not released)	
			Closed distal radial & ulnar fracture	Tie-in				
		Snowy owl (x3)	Open oblique midshaft radial & ulnar fracture	Type 1				Died during anesthesia
			Open proximal radial & ulnar fracture (x2)	Type 1				Both radial & ulnar fractures healed (died)
			Open comminuted midshaft radial & ulnar fracture	Tie-in				
		Sharp-shinned hawk (x5)	Open oblique midshaft radial & ulnar fracture	Tie-in				Released
			Open transverse midshaft radial & ulnar fracture	Type 1				
			Open oblique proximal radial & ulnar fracture	Type 1				Ulnar fracture healed only (not released)
		Red-tailed hawk	Closed proximal radial & ulnar fracture	Tie-in				Ulnar fracture healed only (not released)
			Closed transverse midshaft radial & ulnar fracture	Tie-in			Low motion range of carpal joint	Ulnar fracture healed only, with a low carpal joint extension (not released).
			Closed transverse proximal radial & ulnar fracture	Tie-in				Ulna radiectomy (not released)
Short-eared owl (x3)	Open proximal radial & ulnar fracture	Tie-in				Ulnar fracture healed only (not released)		
	Open distal radial & ulnar fracture	Tie-in				Ulnar fracture healed only (not released)		

Data summary table (continue)

Author	Year	Species	Orthopedic condition	ESF type	Complications	Radiography & clinical findings	Remarks			
Vergneau-Grosset et al.	2020	American kestrel	Open proximal radial fracture	Type 1			Ulnar fracture healed only (not released)			
			Open comminuted midshaft radial & ulnar fracture	Type 1			Released			
			Broad-winged hawk (x3)	Open proximal radial & ulnar fracture (x2)	Tie-in			Ulna radiectomy (not released)		
			Peregrine falcon	Closed oblique distal radial & ulnar fracture	Tie-in			Both radial & ulnar fractures healed (not released)		
			Cooper's hawk	Open comminuted midshaft radial & ulnar fracture	Tie-in			Ulnar fracture healed only (not released)		
			Barred Owl	Closed transverse distal radial & ulnar fracture	Tie-in			Ulnar fracture healed only (not released)		
			Turkey vulture	Closed transverse proximal radial & ulnar fracture	Tie-in	Malunion		Both radial & ulnar fractures healed malunion occurred (not released)		
			Great horned owl	Closed midshaft radial & ulnar fracture	Tie-in			Released		
			Rosenthal et al.	1994	Moluccan cockatoo	Open stifle joint luxation (arthrodesis)	Type 1	Severe derangement, secondary cartilage damage	Day 26: signs of bony fusion of femur to tibiotarsus. Day 47: bony remodeling at the arthrodesis site. Day 90: continuation of bony remodeling. Month 7: increase in bony fusion.	The luxation was closed, but the distal femur had perforated the skin.
						Closed stifle joint luxation	Type 1	50% reduction in motion range of elbow		Five weeks after surgery the joint recovered its motion range.
Martin et al.	1993	Great horned owl	Closed elbow luxation	Transarticular	20% reduction in motion range of elbow		With physical therapy motion range of the elbow recovered, and the bird was released.			

Data summary table (*continue*)

Author	Year	Species	Orthopedic condition	ESF type	Complications	Radiography & clinical findings	Remarks
		Prairie falcon	Open elbow luxation	Transarticular	The motion range of the elbow joint was restricted to 90 degrees		There was a proximal radial fracture on the same wing. The fracture was treated with an IM pin (bird kept for teaching purposes)
		Prairie falcon	Closed elbow luxation	Type 2	Decrease in elbow's range of motion		With physical therapy motion range of the elbow recovered, and the bird was released
Carrasco et al.	2017	Pet birds (x35)	Tibiotarsal fracture	Tie-in	Osteolysis (x3) New fracture during removal of IM pin (x2) Minor malunion (x1)		27/35 fractures healed

